



Learning From Others:

Anesthesia
Quality Institute 
ANESTHESIA INCIDENT
REPORTING SYSTEM (AIRS)

A Case Report From the Anesthesia Incident Reporting System

Review of unusual patient care experiences is a cornerstone of medical education. Each month, the AQI-AIRS Steering Committee abstracts a patient history submitted to the Anesthesia Incident Reporting System (AIRS) and authors a discussion of the safety and human factors challenges involved. Real-life case histories often include multiple clinical decisions, only some of which can be discussed in the space available. Absence of commentary should not be construed as agreement with the clinical decisions described. Feedback regarding this article can be sent by email to airs@asahq.org. Report incidents or download the AIRS mobile app at www.aqiairs.org.

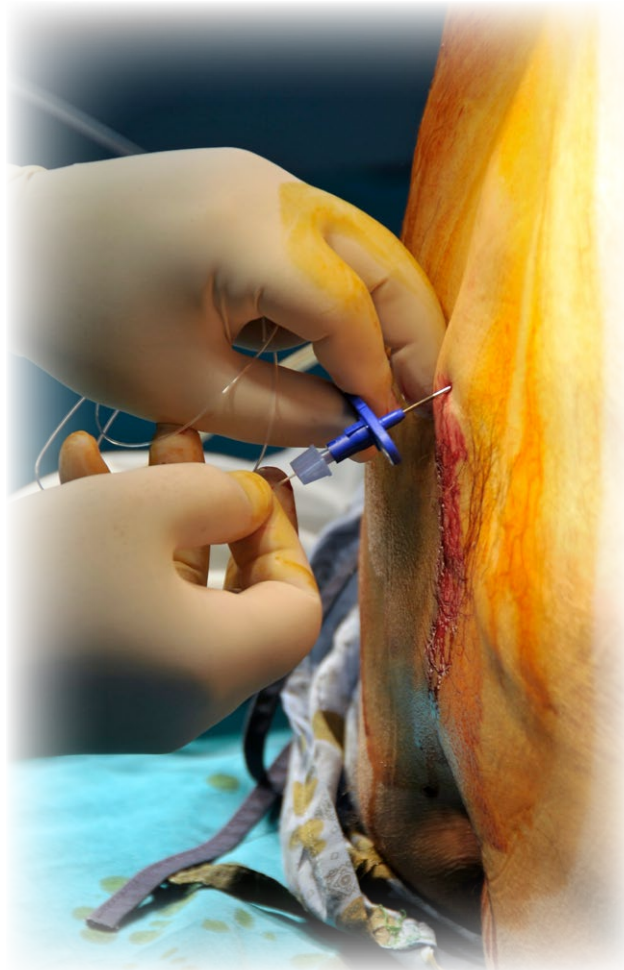
Case 2017-03: Don't Forget the Tip

We had an epidural catheter break off and remain in the patient's back. Typically, after delivery the OB nurses will pull the epidural catheters for us. The OB nurse reported increased resistance and called the anesthetist. The anesthetist attempted to remove the catheter, re-positioning the patient several times. After five attempts at removal the catheter was recovered, minus the distal 6 cm.

Discussion:

Complications can occur despite the best efforts of the anesthesia team. It is possible that this event could have been prevented by cessation of efforts to remove the stuck catheter, with transport to radiology for fluoroscopic or even semi-open removal. It is just as likely, though, that the catheter would break off anyway, perhaps due to a partial shear incurred during its placement. There is little in the literature to suggest that the expense and inconvenience of such a clinical escalation is justified – most stuck epidural catheters are eventually removed intact with gentle traction and returning the patient to the anatomic position in which the catheter was placed.

So what now? An important role of an anesthesia group's quality improvement and risk management leadership is training for all providers. Not just in the science of the event, but also in the broader professional issues of how to react to unexpected adverse events. In the present case, this includes prompt disclosure of the complication to the patient, who is likely to suspect that everything is not perfect, and prompt notification of group and hospital leaders. Confidence in knowing what to do will mitigate the emotional impact on providers. A clear understanding of the steps to follow after a complication, including knowledge that department leadership will support the provider's actions, will contribute to a positive safety culture in the group.



As to the best scientific practice for managing a retained epidural catheter tip, prospective randomized trials of best management are sadly lacking in the literature, perhaps due to a shortage of volunteers to study. Expert opinion leans toward leaving the catheter tip in place. The risks of attempted removal are thought to outweigh the potential benefits of doing so.

“Confidence in knowing what to do will mitigate the emotional impact on providers. A clear understanding of the steps to follow after a complication, including knowledge that department leadership will support the provider’s actions, will contribute to a positive safety culture in the group.”

Pincirolì and Fumigalli reported one such retained catheter which was in place for 12 years before its incidental discovery. A review of retained spinal catheter tips noted the occurrence of patient symptoms in about a third of cases, although epidural catheters are presumably less likely to cause problems. An excellent review by Mithra and Fleischmann made the following recommendations for management of stuck or sheared catheters:

1. Using slow continuous force [for removal] at all times
2. Discontinuing application of force if the catheter begins to stretch and reapplying traction several hours later
3. Placing the patient in the same position as insertion
4. Placing the patient in the lateral decubitus position if possible
5. Attempting to remove in extreme flexion if the previous interventions are not efficacious
6. Attempting extension if flexion fails
7. Attempting removal after injection of preservative-free normal saline through the catheter
8. Considering use of a convex surgical frame
9. Considering computed tomographic scan to identify the etiology of entrapment
10. Considering leaving a retained epidural catheter in place in adult patients
11. Providing patient education regarding “red flags” to watch out for
12. Neurosurgical consultation for all cases in which the catheter fragment is in the spinal canal.

Let’s pick up the story, as reported to AIRS:

The occurrence was promptly disclosed to the patient, who reported no symptoms of pain, paresthesia or infection. A CT scan was obtained and the remaining catheter could be clearly identified due to its wire coil; 1 cm remained in the epidural space with 5 cm tracking back through the interspinous ligaments and tissue. The catheter did not appear to be kinked or knotted.

The patient was not upset by the complication. The team advised the patient that removal was possible, but not recommended. The patient was not upset, and initially declined surgery. On the day of scheduled discharge, however, the patient changed their mind. A neurosurgeon was consulted and the patient taken to the O.R. the next day. Under general anesthesia and with the use of fluoroscopy, the catheter tip was easily removed via a small skin incision.

This outcome is also consistent with the literature: despite the fact that most authors recommend leaving the retained catheter tip in place in an asymptomatic patient, most case reports – and the experience of the AIRS Committee – is that surgical removal almost always occurs. We suspect this is consistent with human nature. The providers feel bad and want to offer the patient something, while most patients are emotionally inclined to have a foreign body taken out. Fortunately, the process of removal can be facilitated with modern imaging technology so as to make the procedure itself as risk free as possible.

In summary, all anesthesia professionals should be prepared to deal with unexpected clinical complications. Understanding the recommended best practice is part of this preparation; more generic knowledge of how to address the event with the patient and institution can be equally useful. Complications can and will occur. Keeping cool and managing in the best interests of the patient are important aspects of professionalism.

Bibliography:

- Pincirolì R, Fumagalli R. The unexpected epidural: a case report. *BMC Anesthesiol.* 2015 Jun 4;15:83. doi: 10.1186/s12871-015-0062-4. PMID: 26041091
- Forsythe A, Gupta A, Cohen SP. Retained intrathecal catheter fragment after spinal drain insertion. *Reg Anesth Pain Med.* 2009 Jul-Aug;34(4):375-8. PMID: 19585702
- Mitra R, Fleischmann K. Management of the sheared epidural catheter: is surgical extraction really necessary? *J Clin Anesth.* 2007 Jun;19(4):310-4. PMID: 17572331.